FLUXOS PAPILARES

Rodrigo Gregório Brandão. Mestrado pela UNIFESP
Pós Graduando - UNIFESP

QUEIXA INICIAL

"Saída de líquido pelo meu mamilo…"

"Isso é normal?"

Espontâneo

Cor

Bilateral

Há quanto tempo

Há outra alteração na mama

Avaliação Clínica

Características do Fluxo Papilar Suspeito
Espontâneos
Unilaterais
Uniductais
Hemorrágicos, sero-hemorrágicos e cristalinos
Associados a nódulo ou retração areolar
Pacientes idosas
Sexo masculino

Brandão RG. MamaNews Jundiaí. 2014

FLUXOS PAPILARES FISIOLÓGICOS

FLUXOS PAPILARES FISIOLÓGICOS

- 5-8% consultas
- Espontâneos
- Bilaterais/multiductais
- Neonatal
- Telarca
- Gestação
- Climatério

Nazário ACP et cols. Mastologia – Condutas Atuais. 2016

FLUXOS PAPILARES FISIOLÓGICOS

Galactorreia

Ectasia Ductal

AFBM

Excesso de curiosidade

Table 2. P-value and Odds-Ratios with 95% CI on the Presence of a Malignancy, a High-Risk Lesion or a Malignancy/High-Risk Lesion for Different Colors of Nipple Discharge Adjusted for the Influence of Age

	Malignant lesion			High-risk lesion			Malignant or high-risk lesion		
Nipple discharge color	Number	p-value	OR (95% CI)	Number	p-value	OR (95% CI)	Number	p-value	OR (95% CI)
Bloody	16	0.32	1.73 (0.58–5.17)	13	0.42	0.67 (0.25–1.78)	29	0.43	1.37 (0.62–3.00)
Clear	1	0.19	3.18 (0.57–17.81)	2	0.21	2.97 (0.55–16.1)	3	0.76	1.30 (0.25–6.89)
White	0			0			0		
Yellow	1	0.68	0.65 (0.08–5.29)	1	0.66	0.63 (0.08–5.12)	2	0.56	0.63 (0.13–2.99)
Green	0	–	–	1	0.83	1.26 (0.14–11.07)	1	0.62	0.59 (0.07–4.95)
Serous	1	0.53	0.52 (0.06–4.19)	3	0.32	1.99 (0.51–7.73)	4	0.70	1.26 (0.38–4.21)
Purulent	1	0.71	1.53 (0.16–14.35)	1	0.93	1.11 (0.12–10.08)	2	0.78	1.27 (0.24–6.61)
Non bloody	4	0.32	0.58 (0.19–1.72)	8	0.42	1.49 (0.56–3.94)	12	0.43	0.73 (0.33–1.60)

Wong Chung et al, 2016

FLUXOS PAPILARES FISIOLÓGICOS

Orientação

Investigação adicional desnecessária

"Deixe o mamilo em paz"

Nature of Discharge	Etiology	Localization	Ducts involved
Milky	Postpartum Medications Hyperprolactinemia Chiari-Frommel syndrome	Bilateral	Multiple
Serous/Serosanguinous	Intraductal Papilloma Intraductal cancer	Unilateral	One
Bloody	Intraductal Cancer Inflammation Trauma	Unilateral	One or two
Green	Fibrocystic Disease	Bilateral	Multiple

Zervoudis et al, 2008

FLUXOS PAPILARES PATOLÓGICOS

FLUXOS PAPILARES PATOLÓGICOS

- Sanguinolentos
- Serosanguíneos
- Transparentes (água de rocha)
- Malignidade 5-11%

Zervoudis; S. Gineco.ro, 2008, Vol. 4.

PAPILOMAS

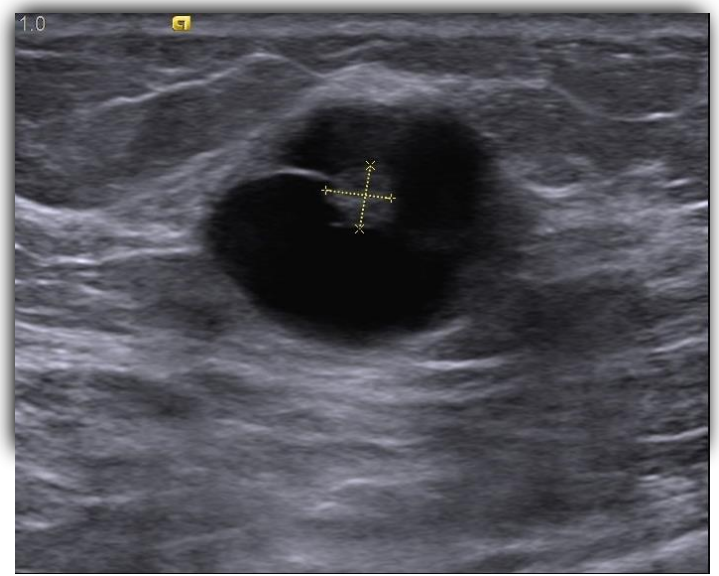

Ueng et al, Arch Pathol Lab Med, 2009

- Causa mais frequente de fluxo sanguinolento 35-62%
- 60-80% sangram
- 35-50 anos
- Preferência ductos retroareolares
- Papilomatose (periférico/múltiplo) x Papiloma Solitário (central)





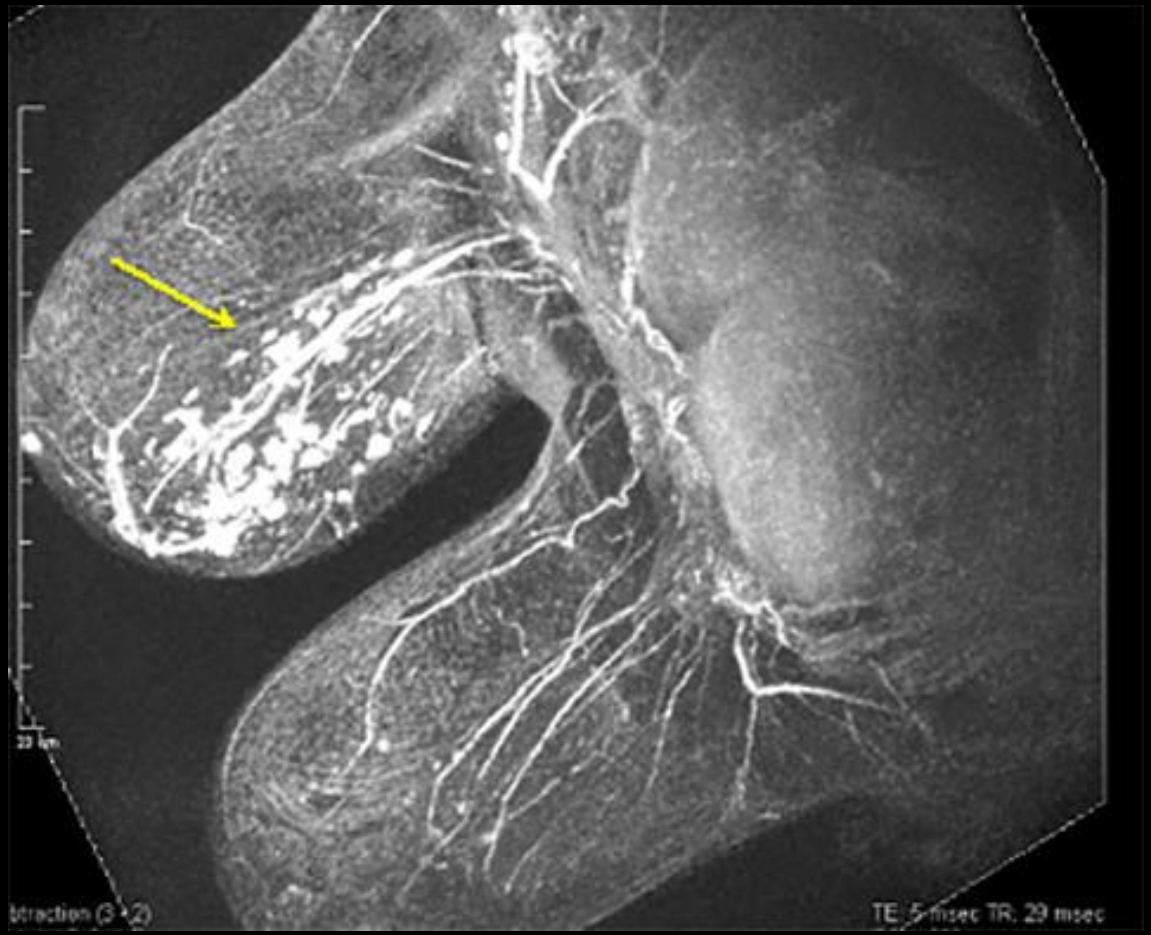
btraction (3 - 2)
TE: 5 msec TR: 29 msec

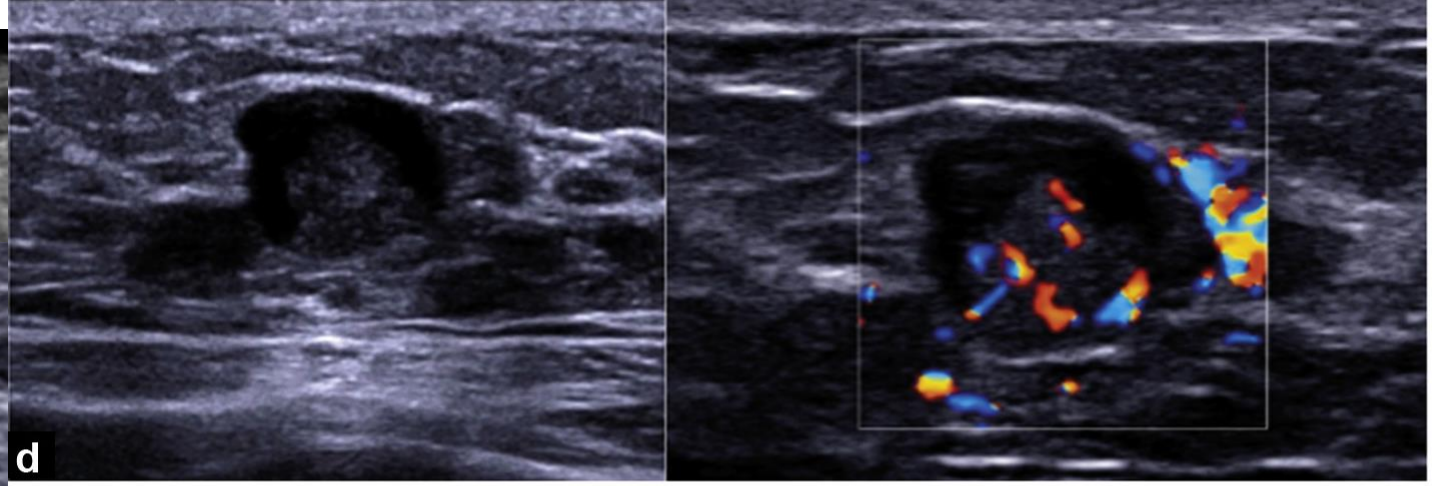
d

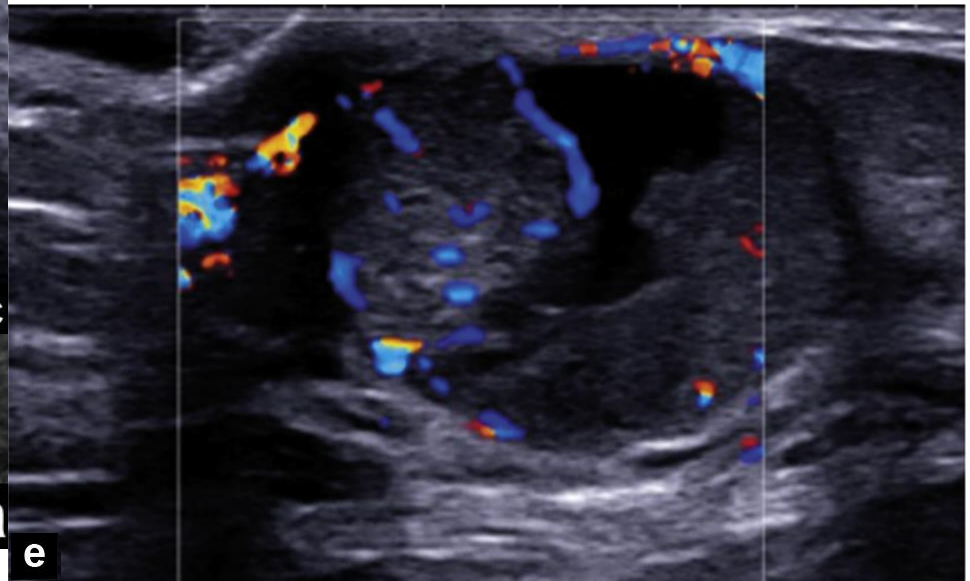
e

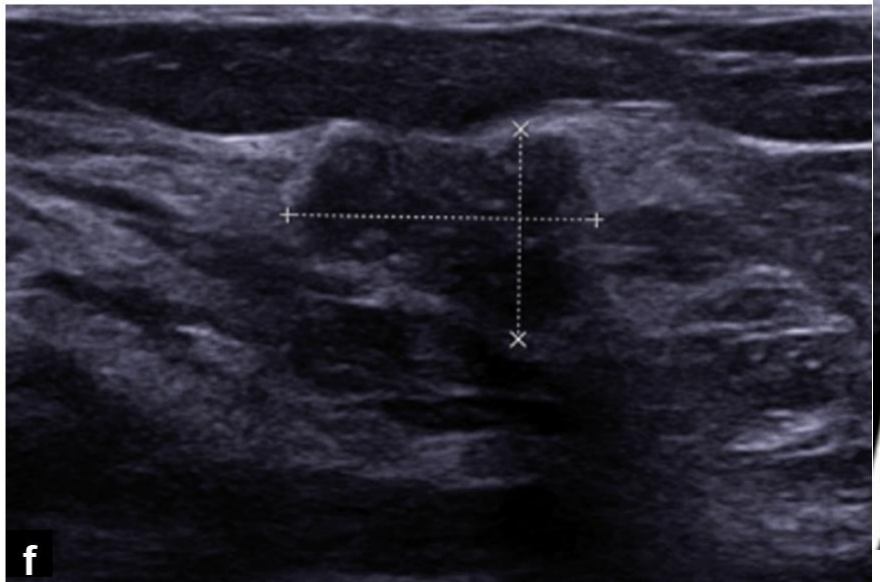
f

ECTASIA DUCTAL

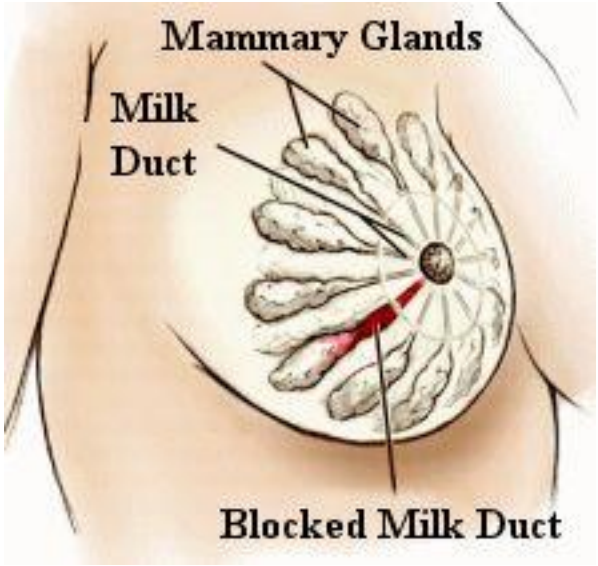

Florio MA, et al. Chirurgia Italiana; 2003

- 11% das causas de fluxo papilar
- Mastite plasmocitária/ mastite periductal/galactoforite
- Processo inflamatório
- Perimenopausa
- Subclínico (1/3 de Mastectomias)

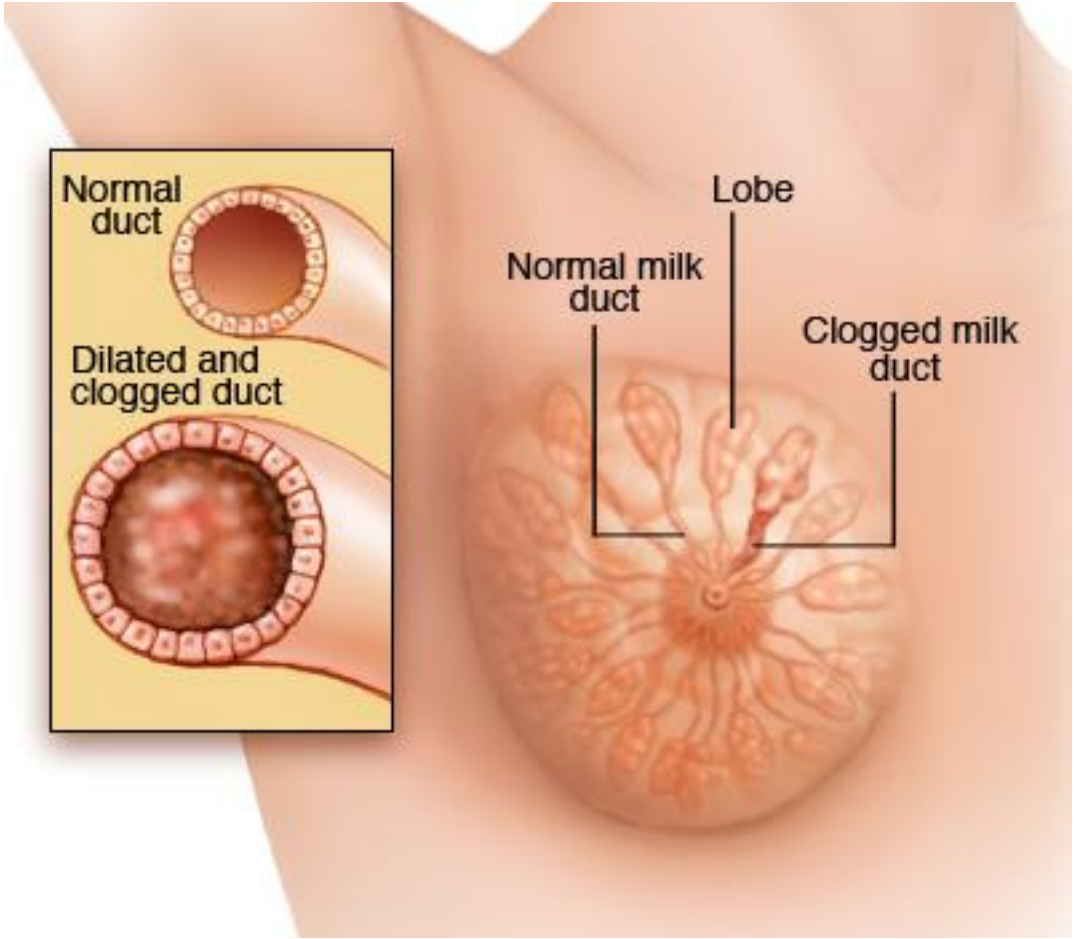

Mayo Fundation for Medical Education

0
1
2

CARCINOMA

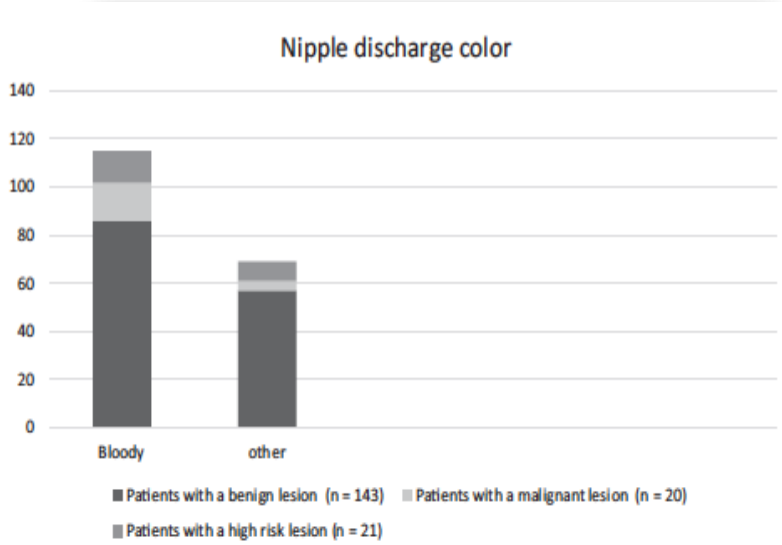

Wong C, et al. The Breast Journal. 2016
Tavassoli, FA. Papillary Neoplasms of the Breast
A Review. 2009

- 5-21% dos fluxos patológicos
- Apresentação Clínica
- Achados Radiológicos
- Papiloma com atipia (menos 1/3)
- Carcinoma papilífero intracístico
- Carcinoma Papilífero (<1%)

CARCINOMA

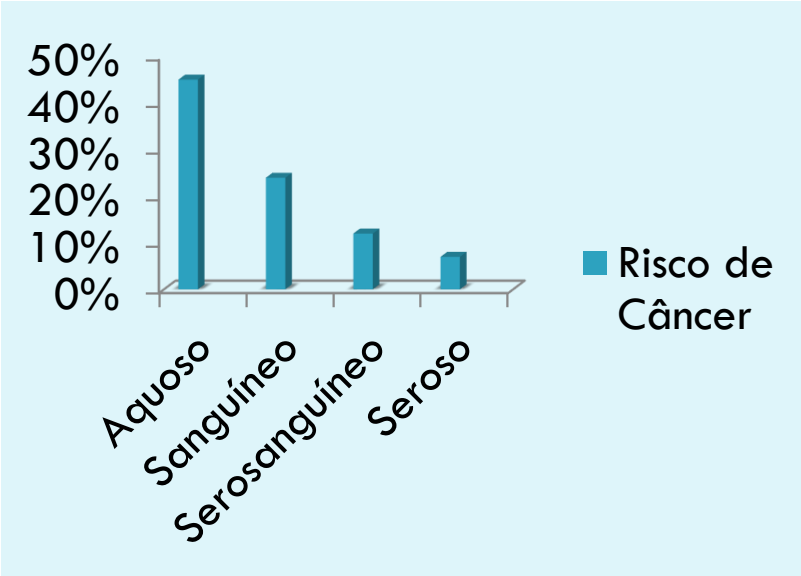

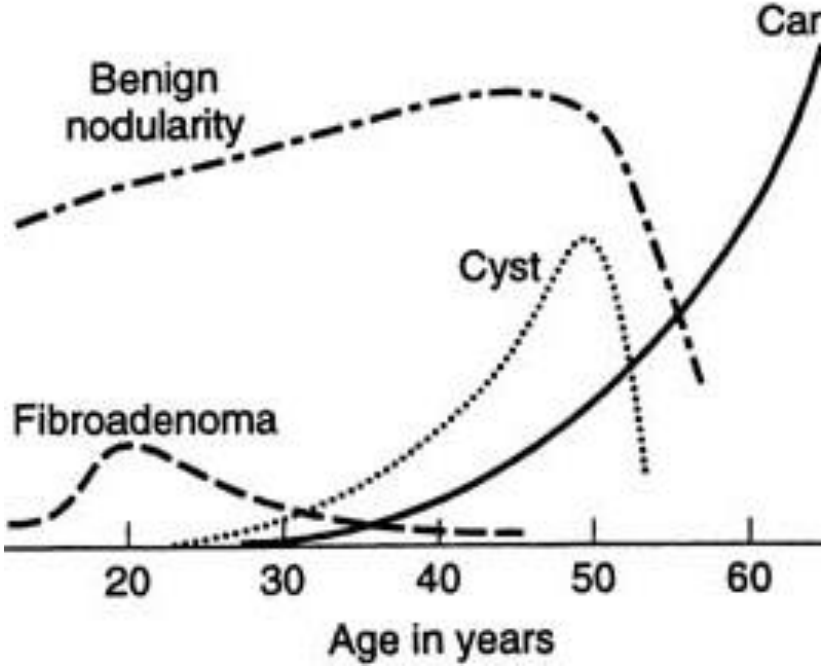

Harris J, et al. 2004
Dupont et al. Surgery. 2015

MMG 6/2012

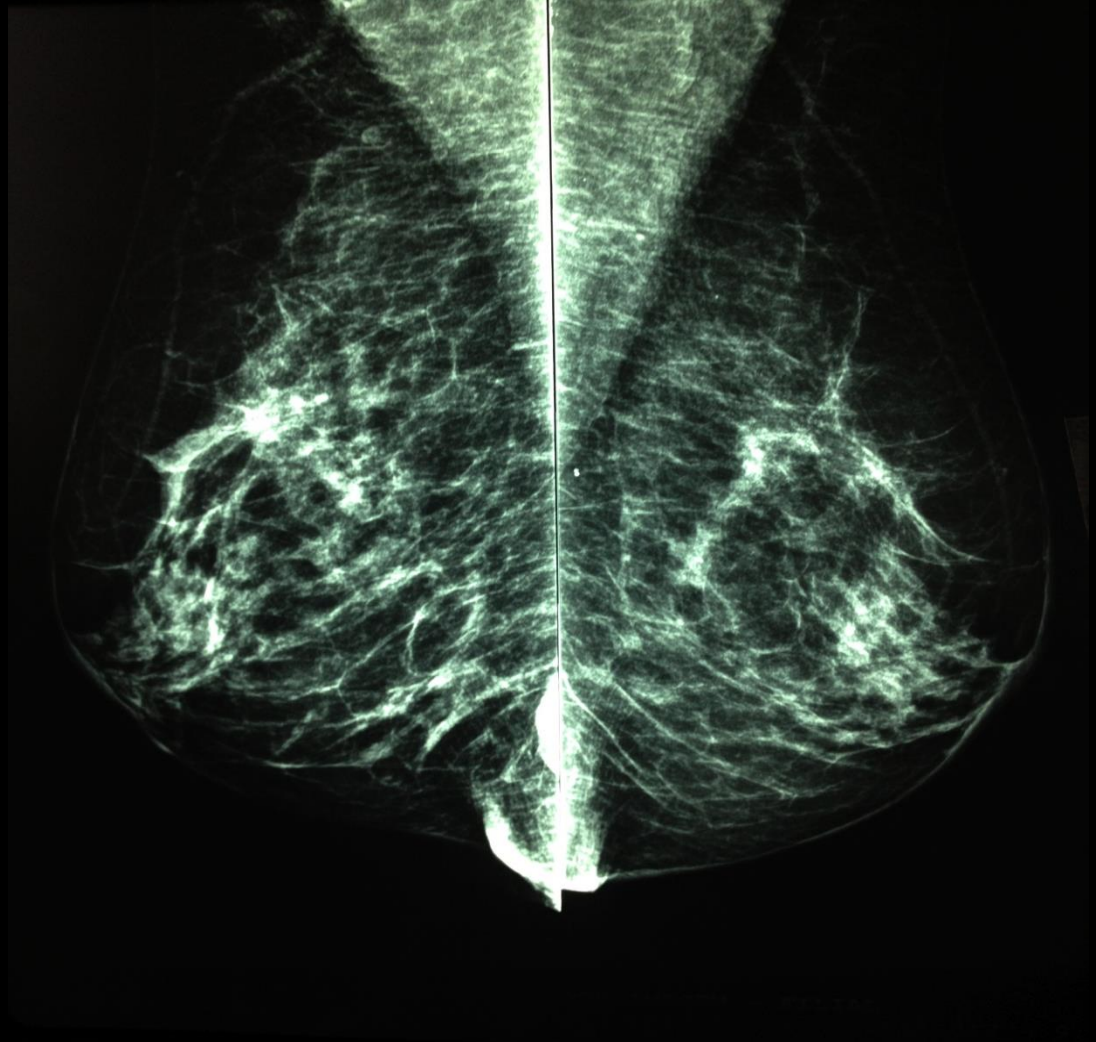

MMG 11/2012

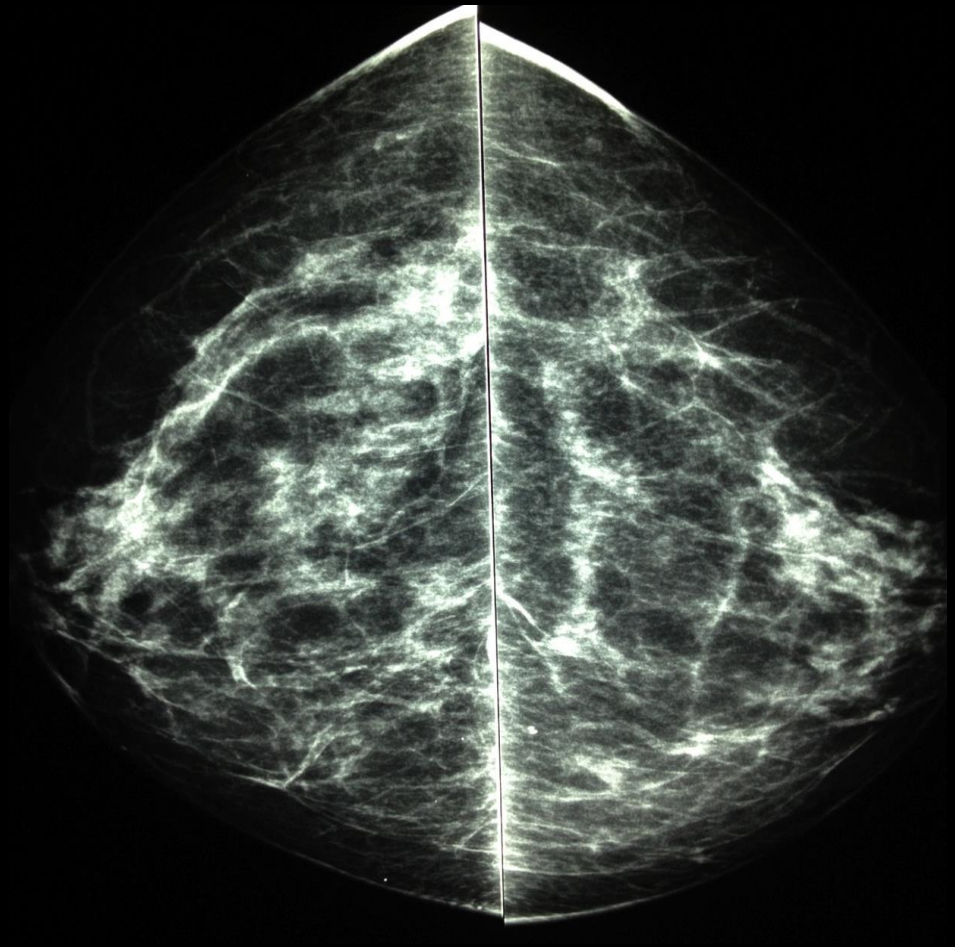

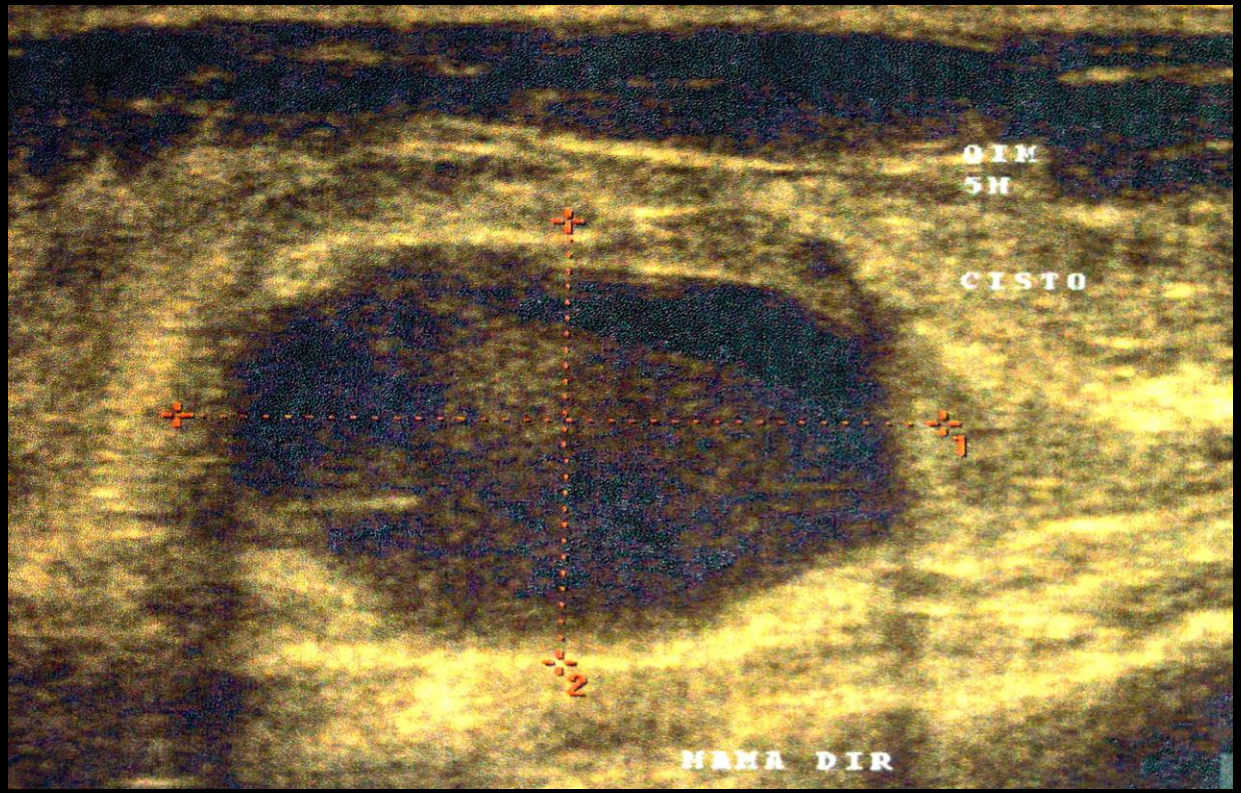
OIM
5M
CISTO
1
2
MAMA DIR

CORE 6/2012

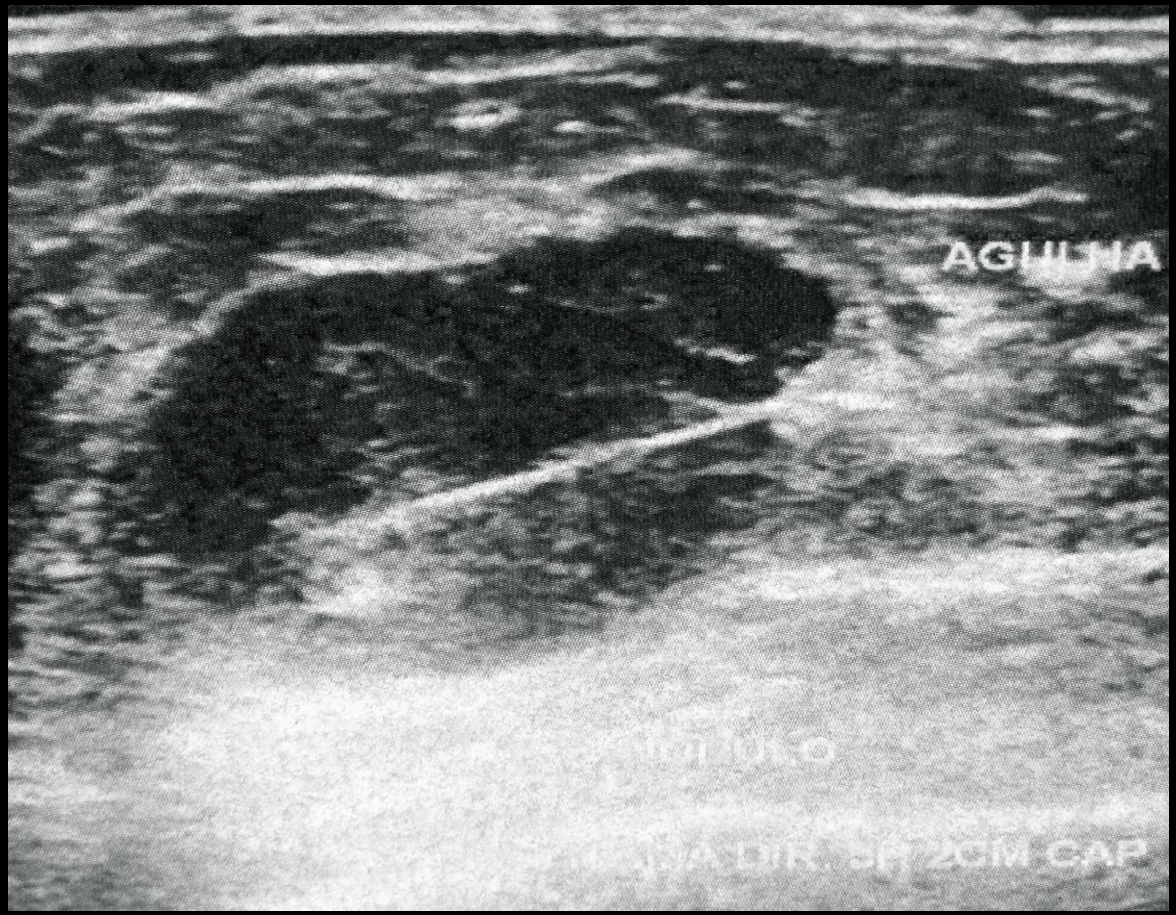

CORE 6/2012

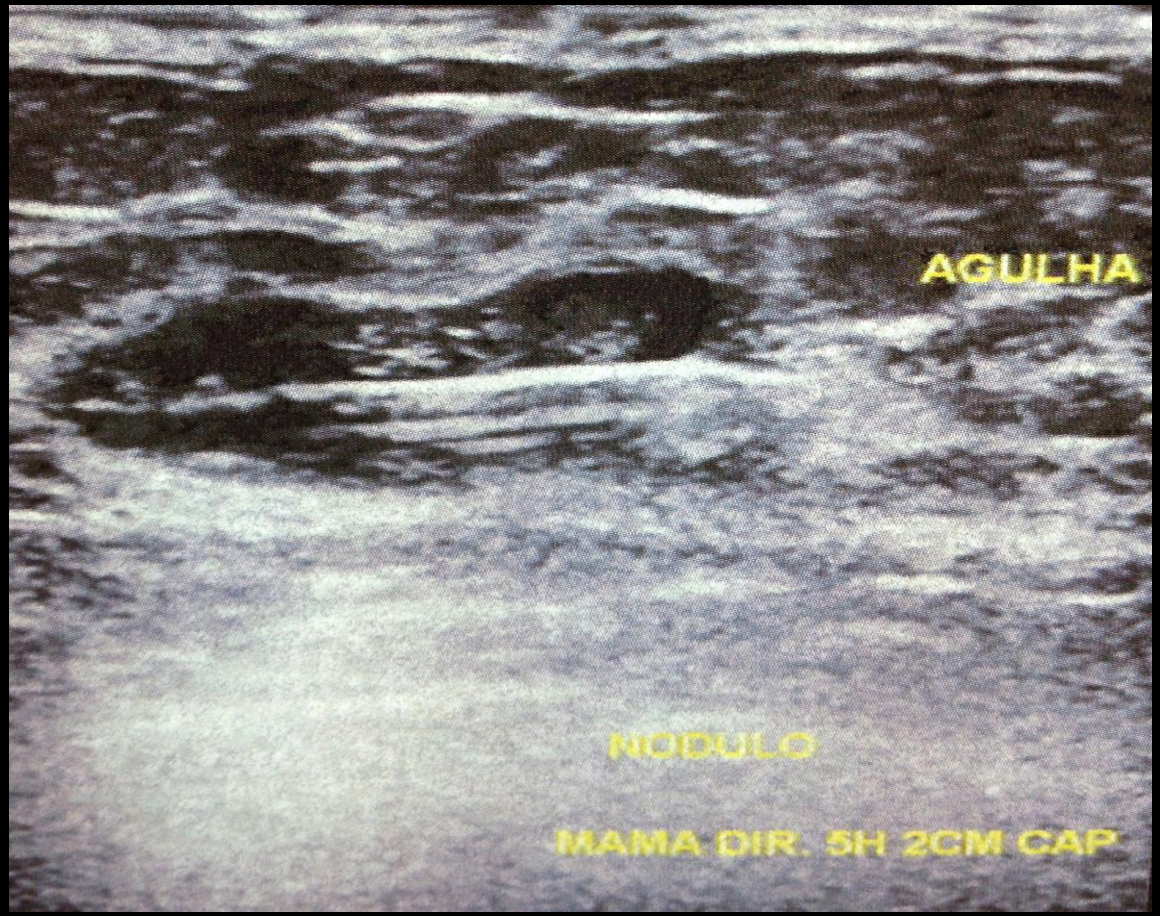

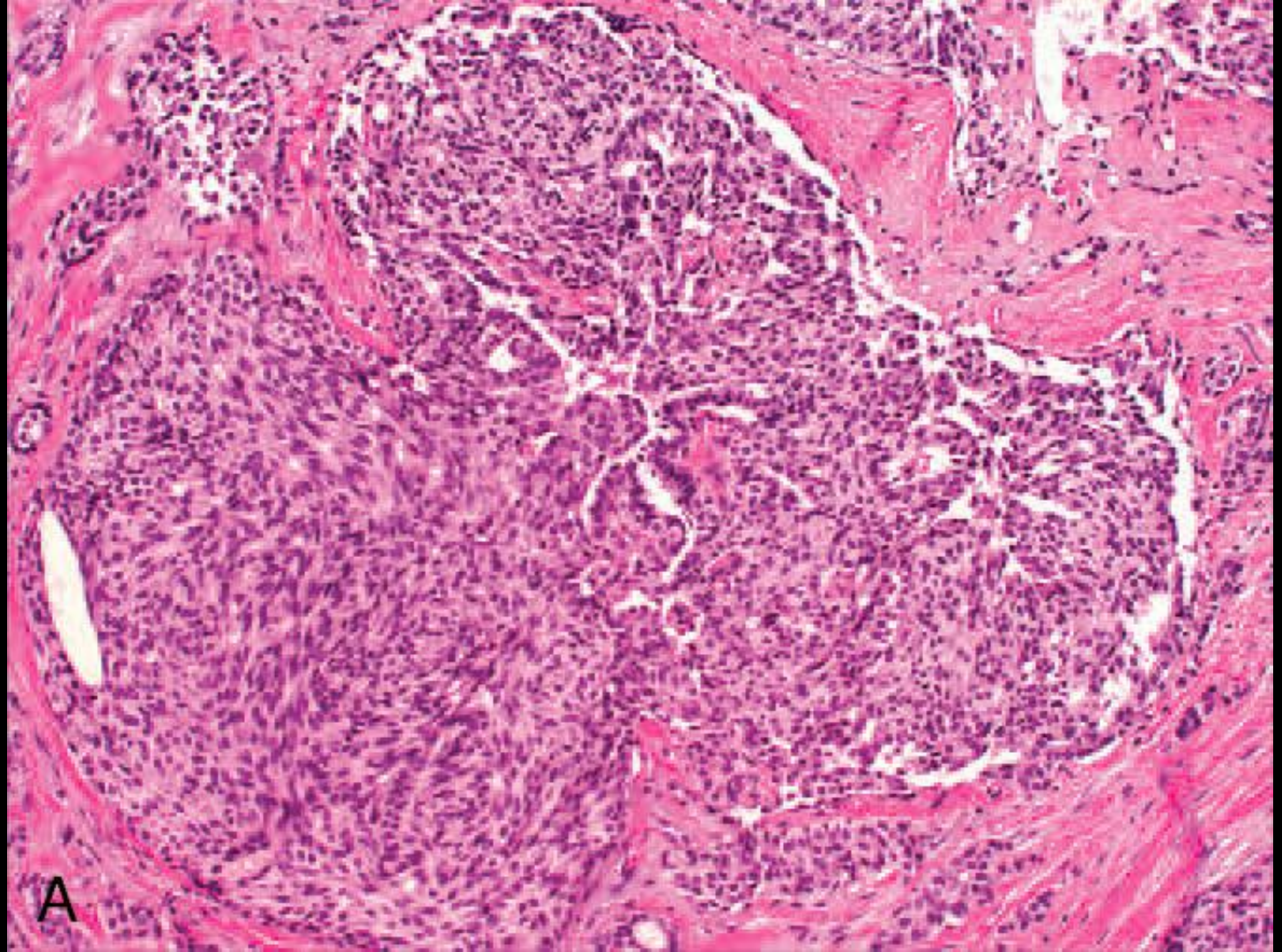
A

INVESTIGAÇÃO DIAGNÓSTICA

DIAGNÓSTICO

- CITOLOGIA
- MMG E US
- TOMOSSÍNTESE
- DUCTOGRAFIA
- DUCTOSCOPIA
- ASPIRADO DUCTAL
- RM

American College of Radiology ACR. Evaluation of Nipple Discharge. 2016

CITOLOGIA

Células atípicas

Hemácias

VPP baixo

VPN baixo

Alto FN

Não localiza a lesão

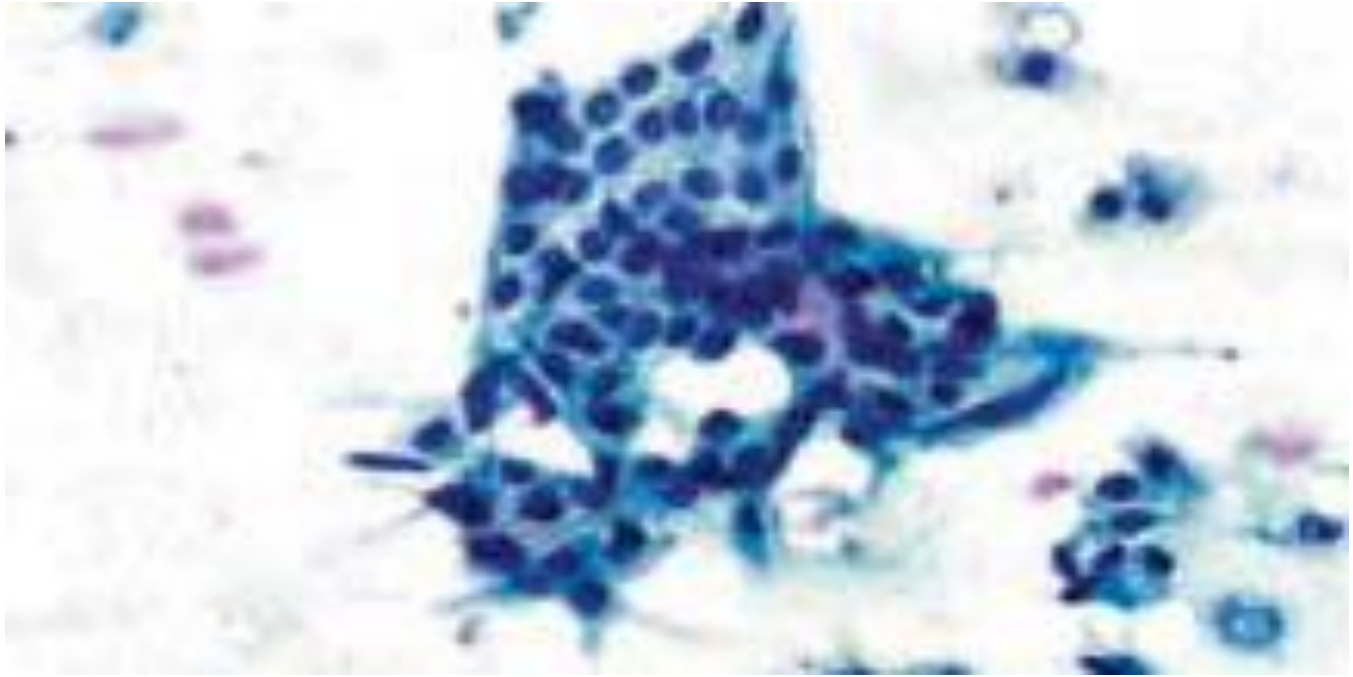

Zervoudis; S. Gineco.ro, 2008

MAMOGRAFIA

Diagnóstica

Incidências adicionais

Calcificações/nódulos /assimetrias

VPP 16,7%

Sensibilidade 59%

½ pacientes sem respostas com MMG

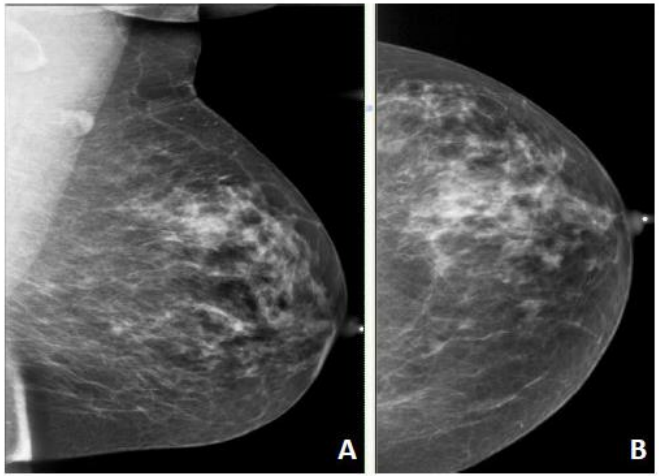

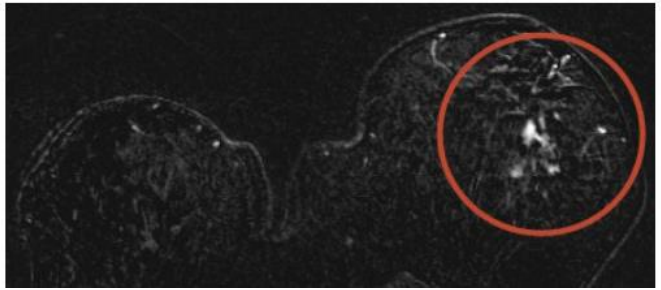

Ito Y, et al. Non-palpable breast cancer with nipple discharge: how should it be treated? Anticancer Res 1997

TOMOSSÍNTESE

MMG 3D

Reduz sobreposição de imagem

MMG simultânea

Reduz FP

Não há estudos neste contexto

Útil (?)

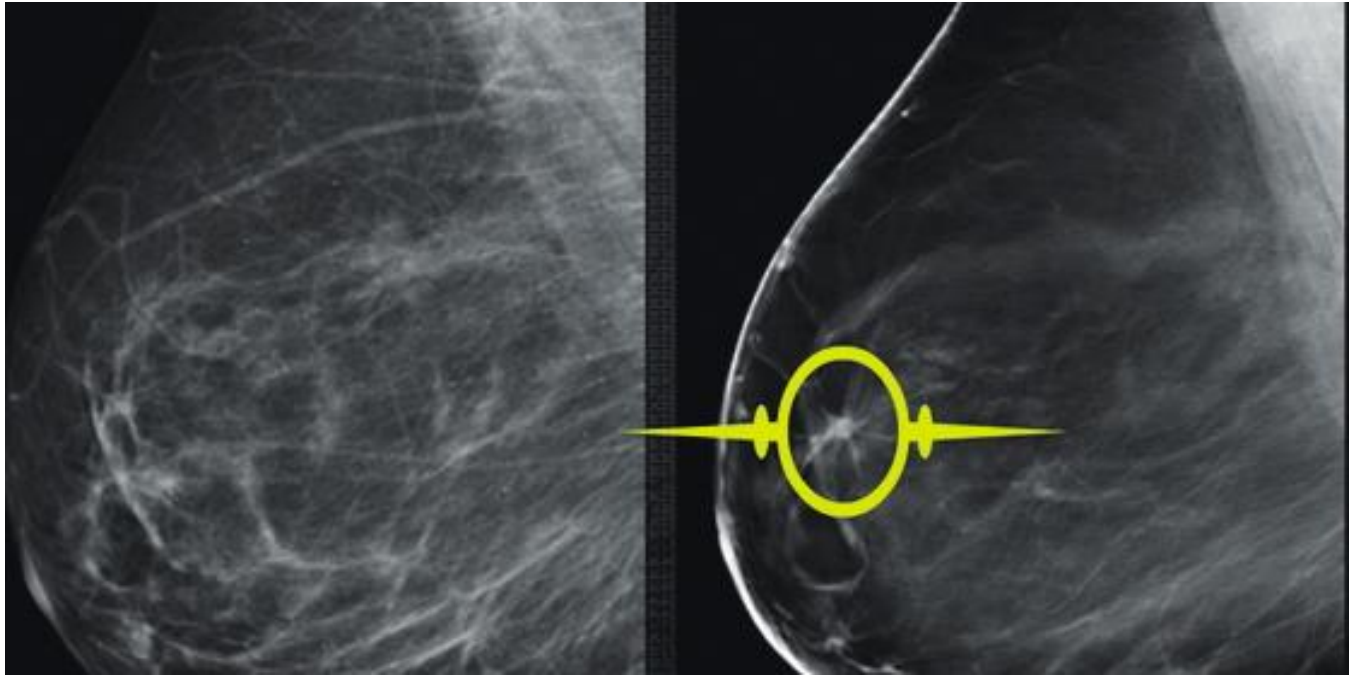

Neto AAF. MamaNews Jundiaí. 2017

ULTRASSONOGRAFIA

Aval. RRA

Reduz sobreposição de imagem

Guiar biópsias

Avaliar extensão

Sensibilidade 65%

Especificidade 75%

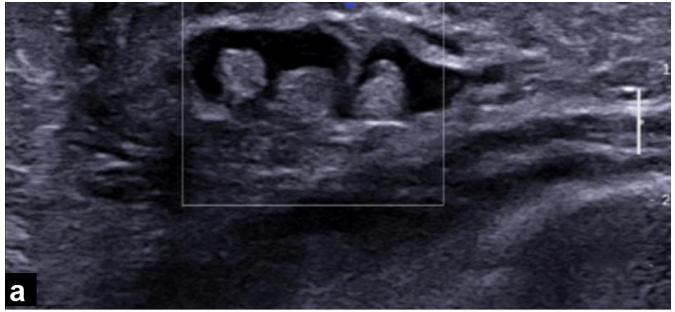

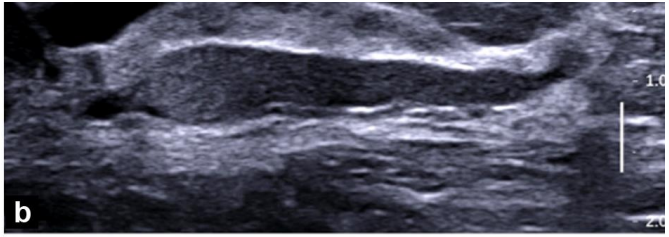

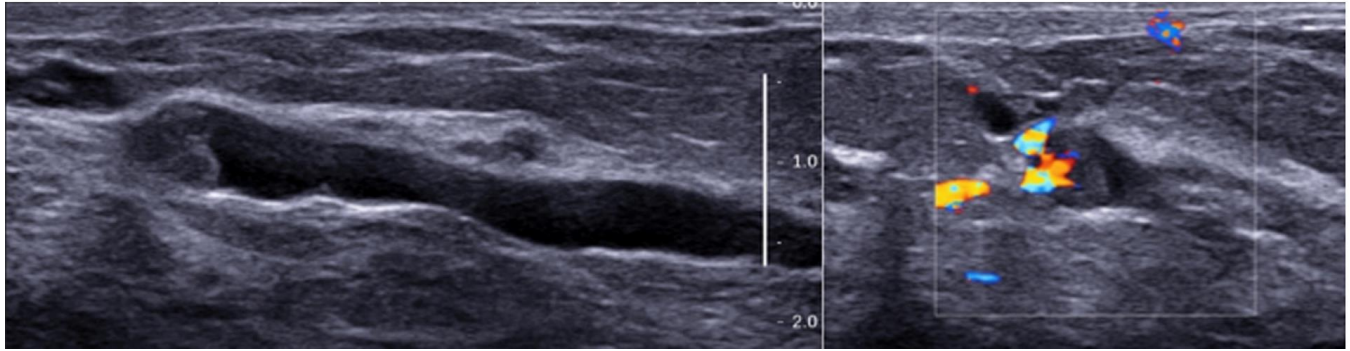

Lippa N. Nipple Discharge: The role of Imaging. 2015

Ductografia

MMG(-) e US(-)

Localizar lesão

"Defeitos de preenchimento"

Lesões periféricas

Desvantagens

Sensibilidade 50%

FN 20%

"Investigation Belonging"

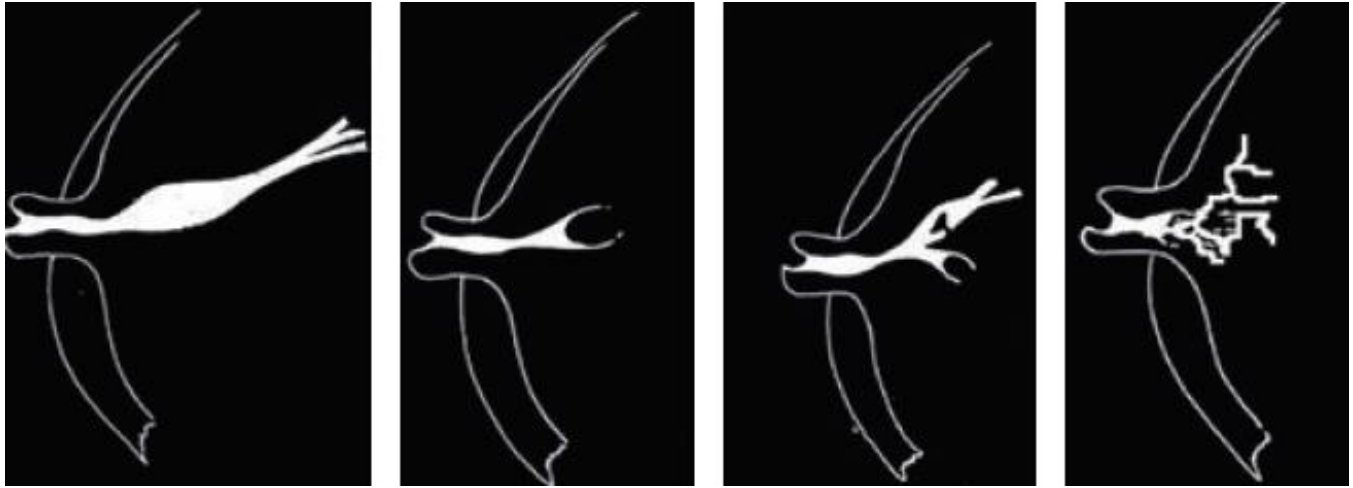

Lippa N. Nipple Discharge: The role of Imaging. 2015

Ductoscopia

Visualização direita

Guiar biópsia

Microendoscópio

Lavagem ductal (mammary pump)

Muitíssimo pouco disponível

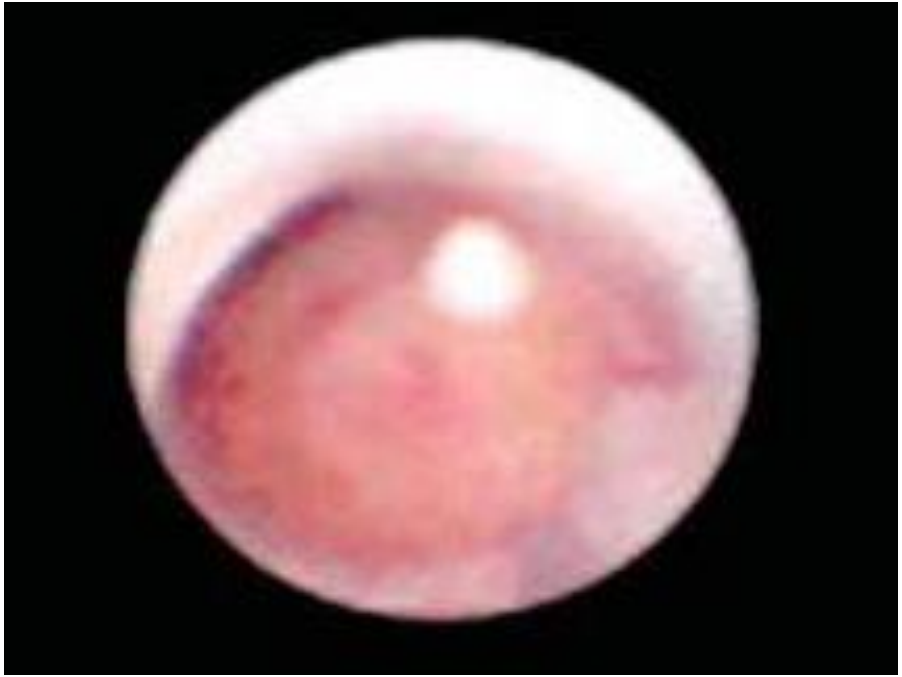

Zervoudis; S. Gineco.ro, 2008

RM

MMG(-) US(-)

Morfológica + fisiológica

Sensib. >93%

Especificidade >37%

Aval. de lesões periféricas

Especialmente útil em casos suspeitos

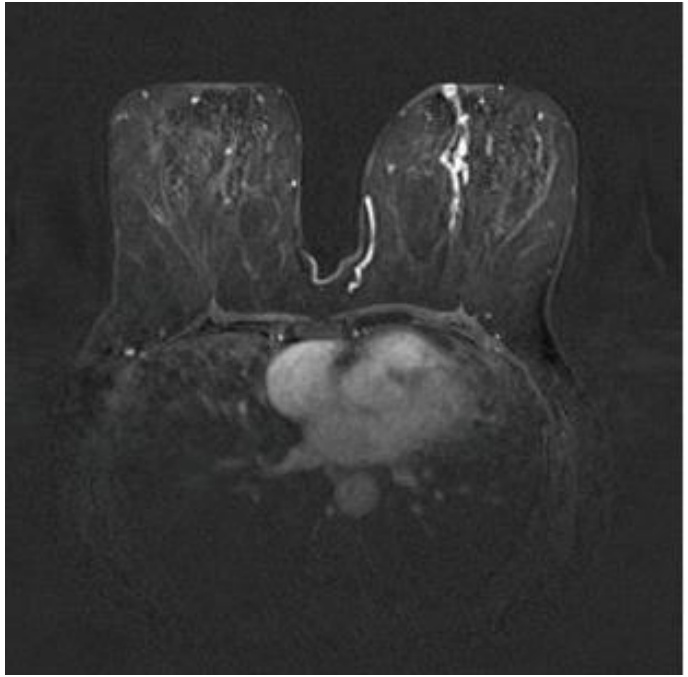

American College of Radiology ACR. Evaluation of Nipple Discharge. 2016

BIÓPSIA PRÉ-OPERATÓRIA – SIM OU NÃO

Evitar Cirurgia

Diagnóstico Pré-operatório

+

Excisão completa da lesão

Resolução dos Sintomas

Diagnóstico Incompleto

Benigno???

-

Taxa de Subestimação

Lesão Residual

BIÓPSIA – SIM OU NÃO

- Lesão palpável
- Risco de malignidade
- E
- I
- P

PADRÃO OURO – RESSECÇÃO COMPLETA DA LESÃO



TRATAMENTO

TRATAMENTO

- Ressecção parcial/única de ductos
- Ressecção completa dos ductos finais

IDADE

EXTENSÃO

ANATOMIA

SINTOMAS

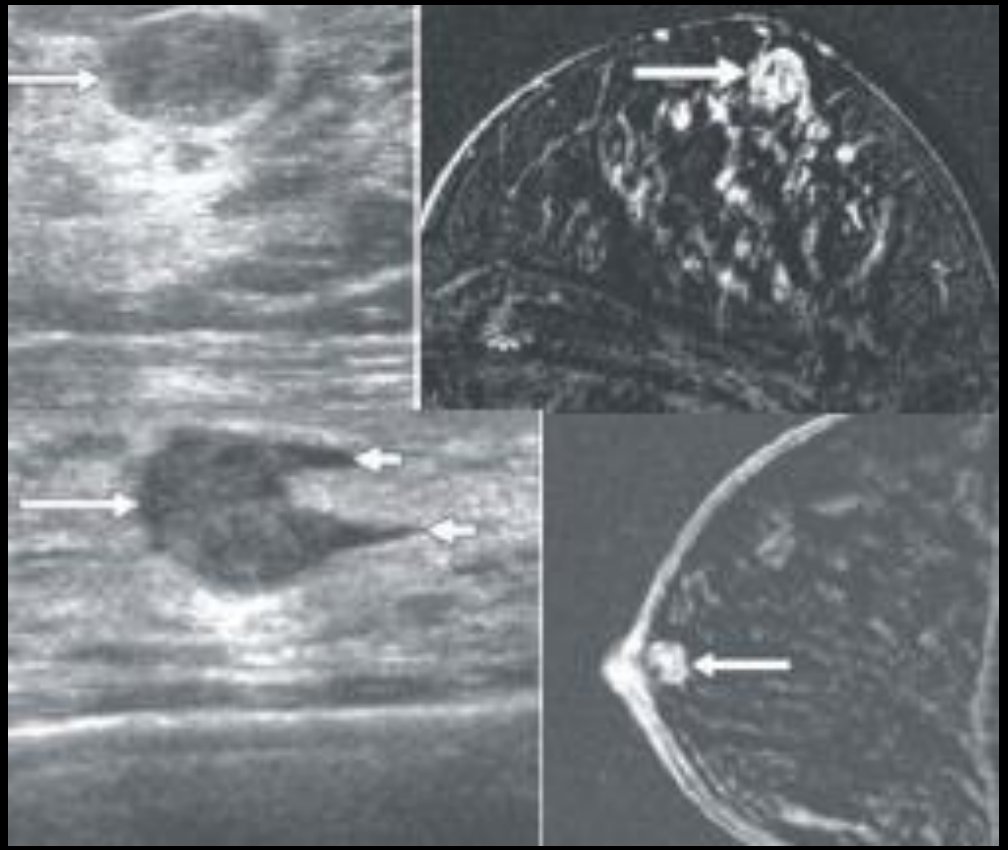

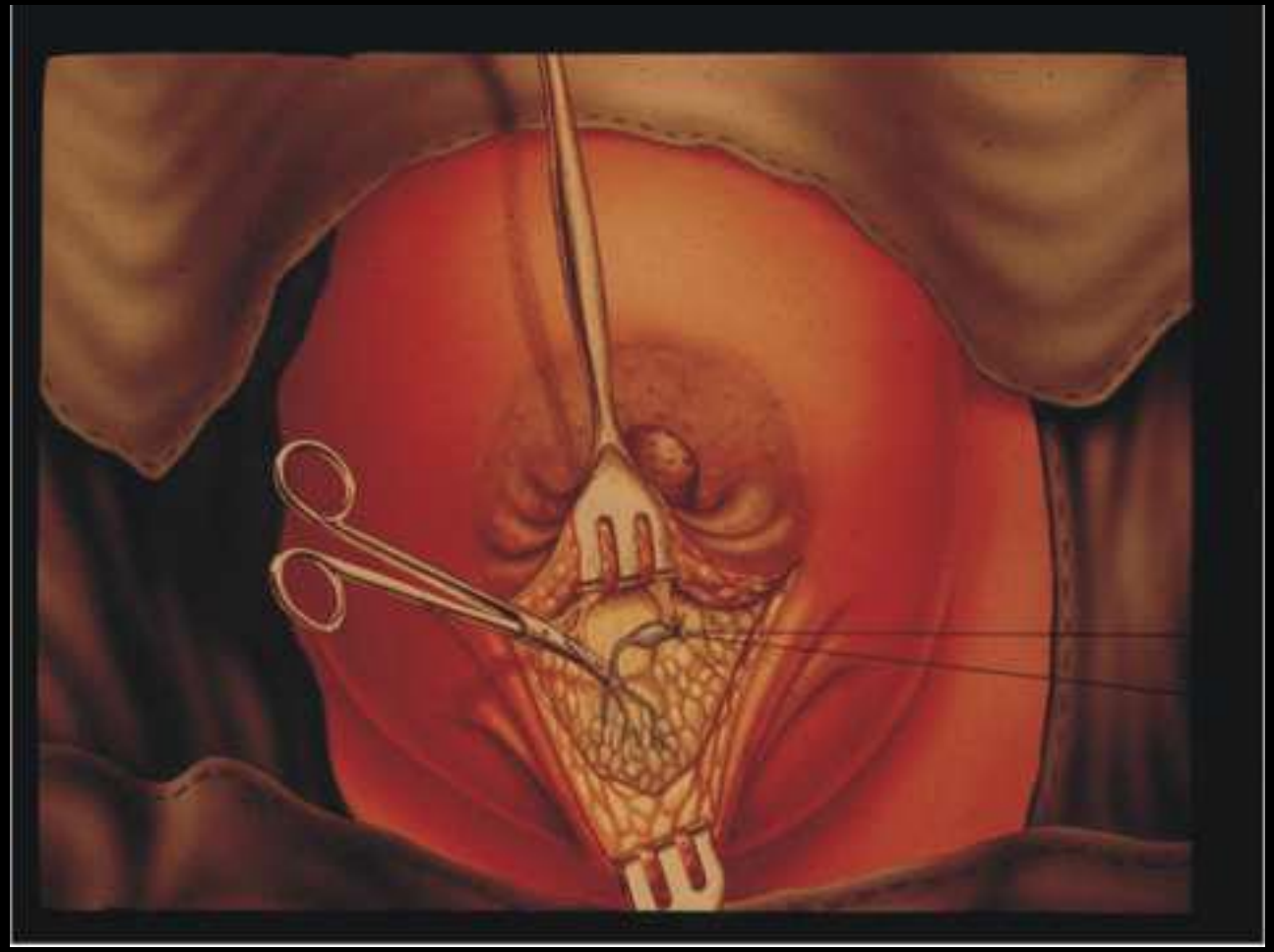

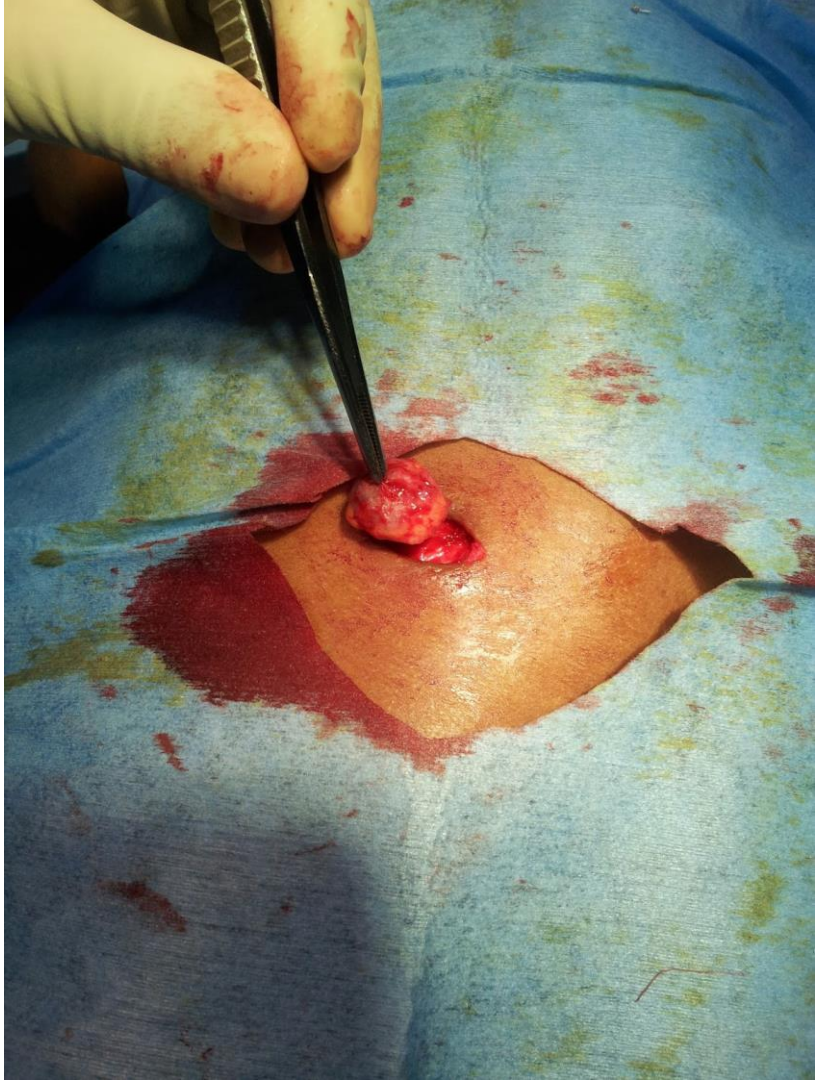

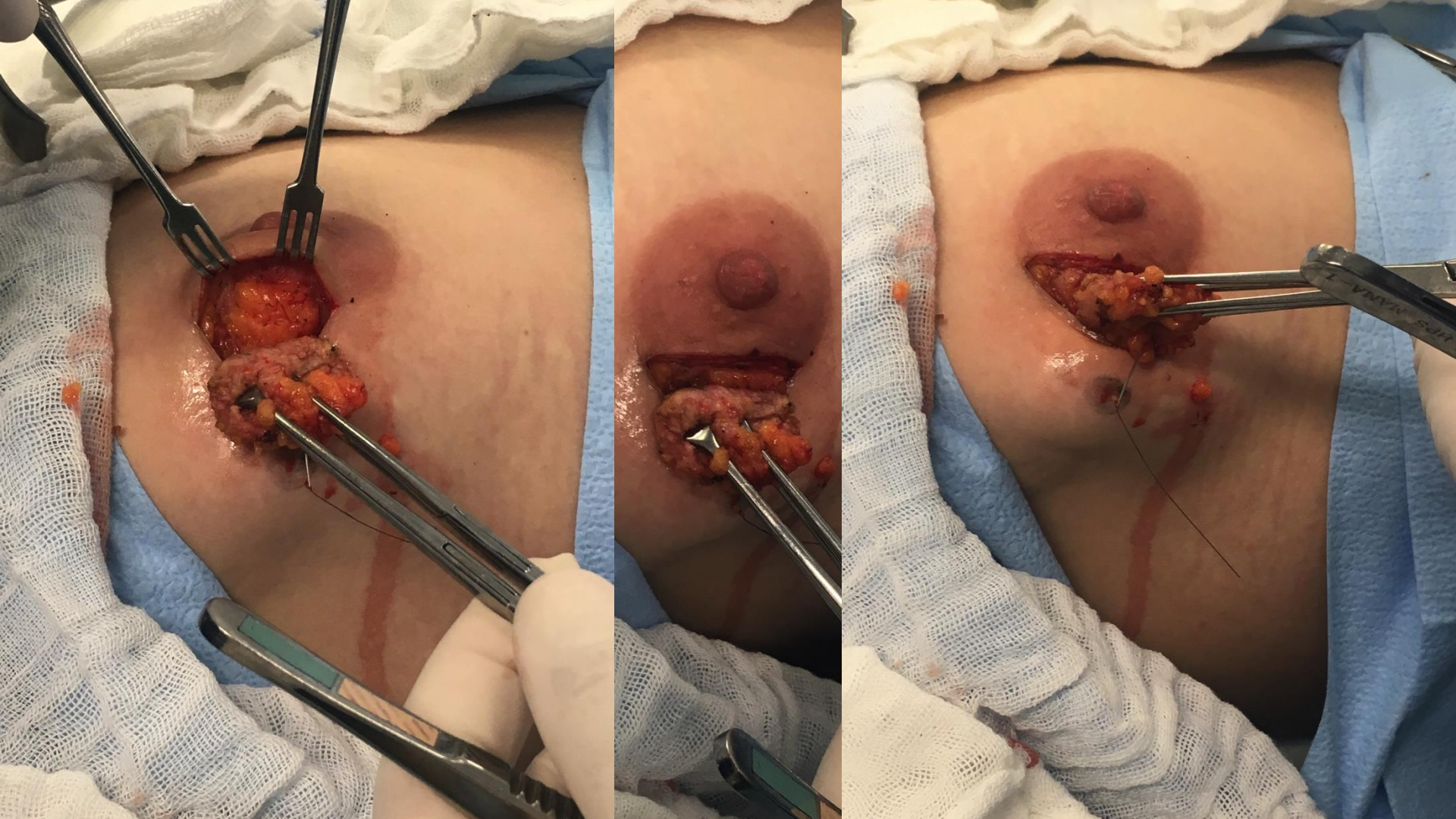

ORDEM E PROGRESSO